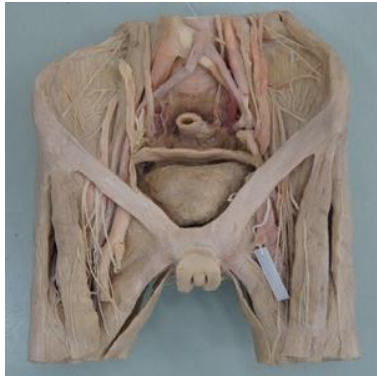
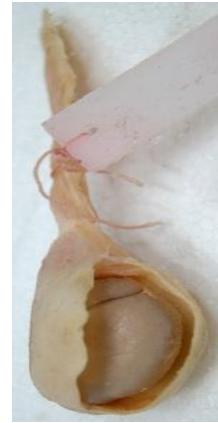
Urogenital system

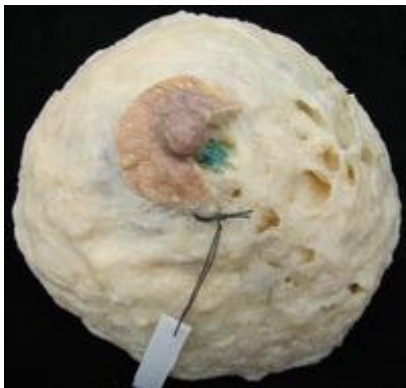Art-No.	Name	Description
SU001	The position of the kidneys, ureters and the urinary bladder.	Reserve the trunk below the diaphragm, with the aorta, inferior vena cava, testicular arteries and veins remained; Showing the costovertebral angle.
SU002	General survey of the male urogenital system	Showing the kidney, urinary bladder, penis and testis etc, isolated from the trunk.
SU003	General arrangement of the female urogenital system	Showing the kidney, urinary bladder, uterus and vulva etc, isolated from the trunk.
SU004	Median sagittal section of male pelvic cavity	Unilateral, showing the prostate, cavernous bodies and urethra.
SU005	Median sagittal section of female pelvic cavity	Unilateral, showing the uterus, ureter and urethra.
SU006	Superior aspect of female pelvic cavity	Showing the position of rectum, uterus and urinary bladder.
SU007	The shape of kidney	Unilateral, showing the structure of renal hilum.
SU008	The coronal section of the kidney	One half, double injected
SU009	The urinary bladder	Showing the trigone of bladder
SU010	The seminal vesicles, ampulla ductus deferentis and prostate	With urinary bladder, showing the trigone of bladder
SU011	The male genital organs	
SU012	The testis and epididymis	Showing the three layers of coats.
SU013	Cavernous body of penis	
SU014	Transverse section of penis	One piece
SU015	Sagittal section of the uterus	
SU016	The female internal reproductive organs	The uterus, uterine tubes, ovaries and a part of vagina.
SU017	The female pudendum	Showing the hymen.
SU018	The female mamma	Bilateral, showing the lobules of mammary gland, septum and adipose tissue of breast etc.
SU019	The placenta	
SU020	Embryos	At different period, soaking in formalin and putting them into organic glass box.
SU021	Fetus	At different period.
SU022	The development of fetal cartilage	Special stained to show the development of fetal cartilage.



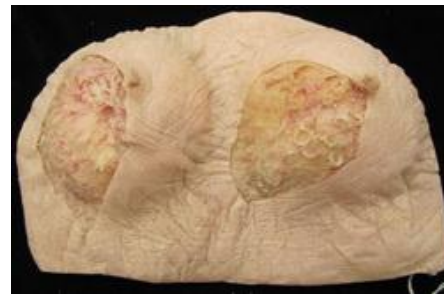The superior view of female pelvic cavity



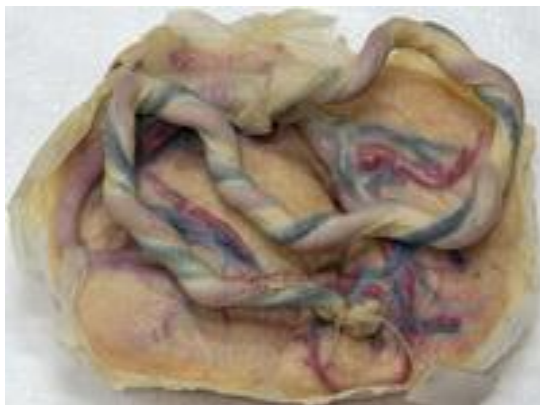Testis and epididymis



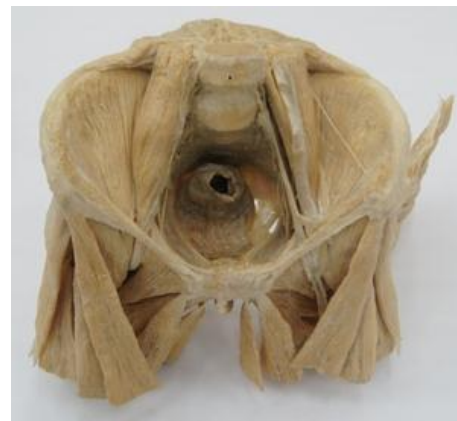Female breast (unilateral)



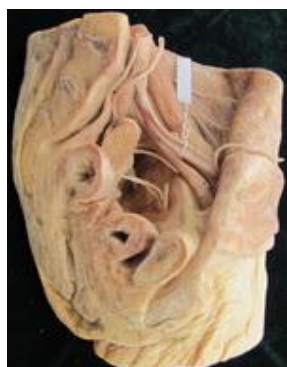Female thoracic wall



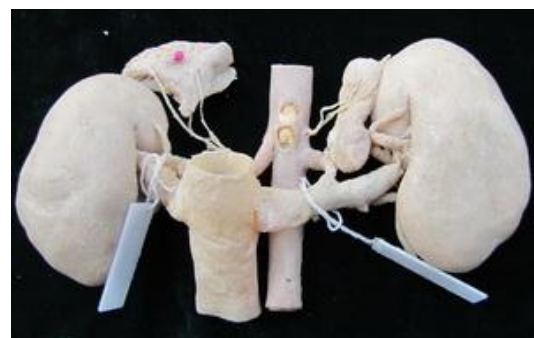Placenta



Muscles of female perineum



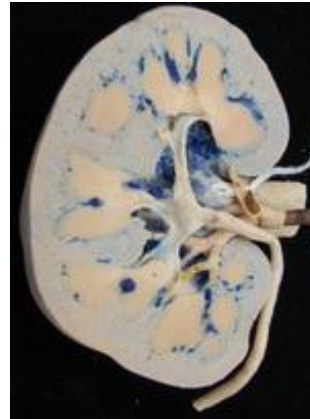Median sagittal section of female pelvic cavity



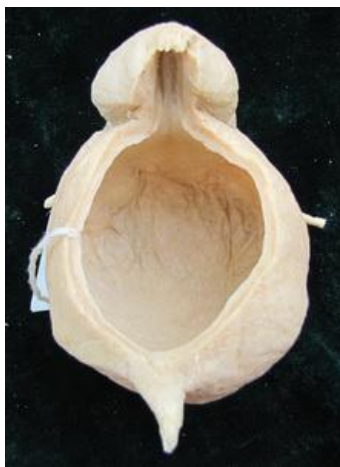Double kidney



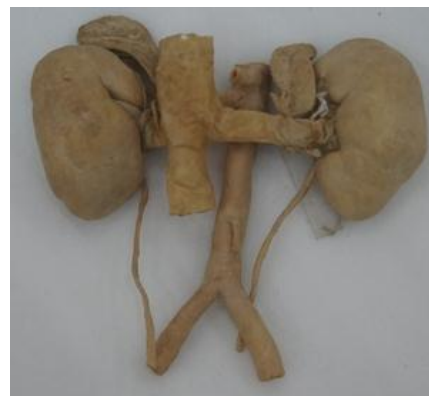Median sagittal section of male pelvic cavity



Coronal section of kidney



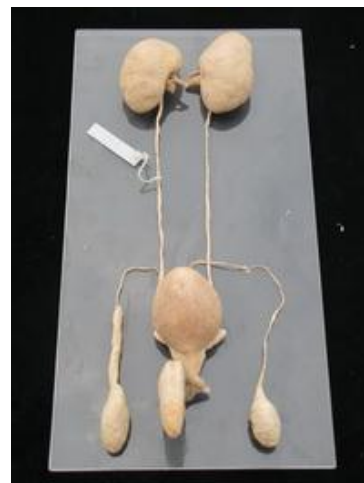
Bladder and the prostatic part of the male urethra



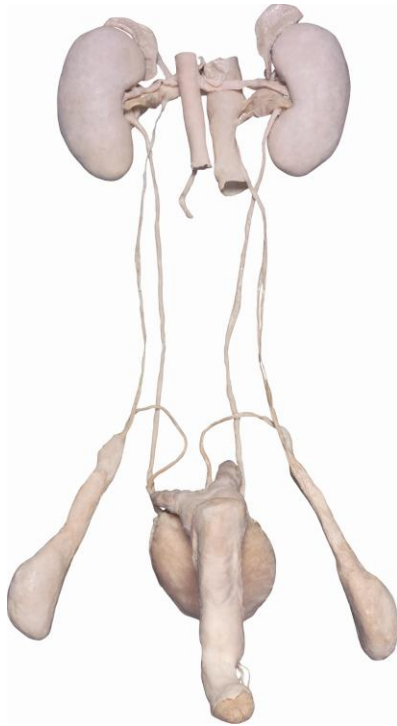
Kidneys and ureters in situ (with suprarenal gland)



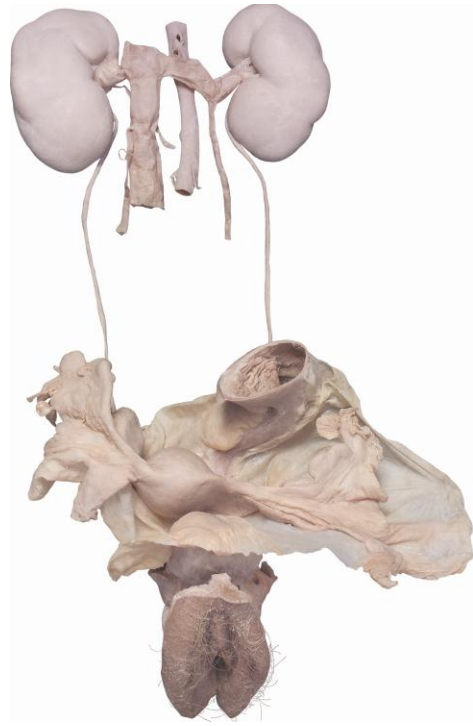General arrangement of female urogenital system



General arrangement of male urogenital system



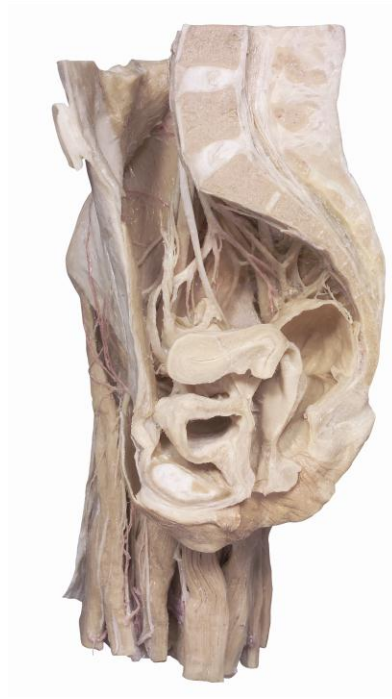Art – N0 / S U 002
male urogenital system



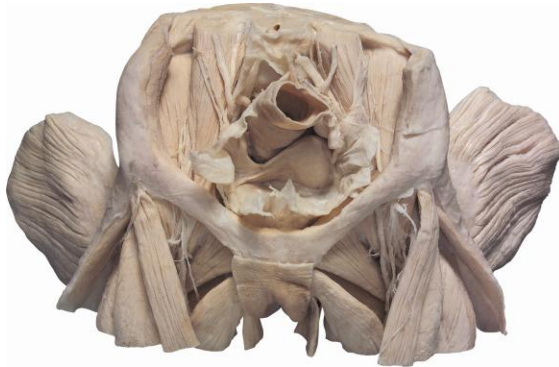Art – N0 / S U 003
female urogenital system



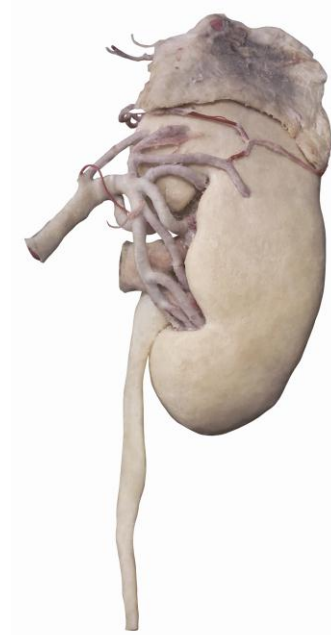
Art – N0 / S U 004
Median sagittal section of male
pelvic cavity



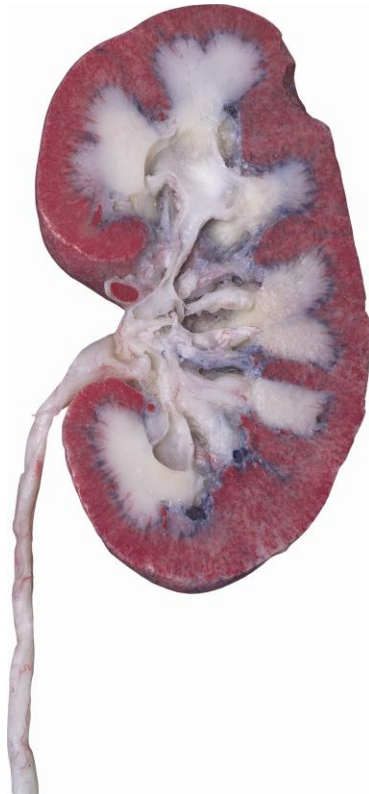Art – N0 / S U 005
Median sagittal section of female
pelvic cavity



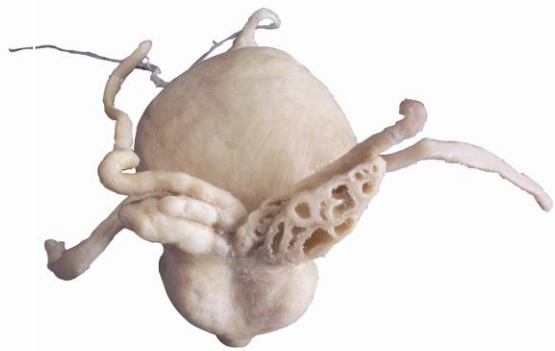Art – N0 / S U 006
Superior aspect of female pelvic cavity



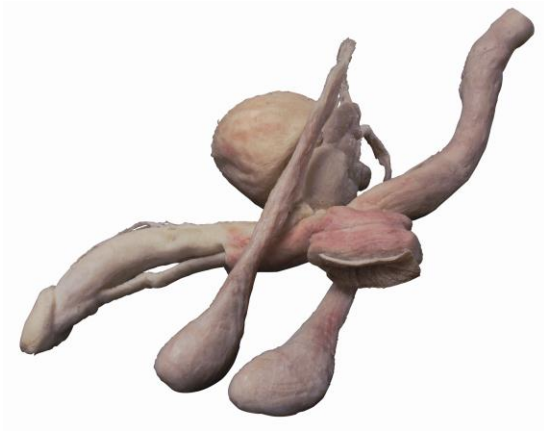Art – N0 / S U 007
The shape of kidney



Art – N0 / S U 008
The coronal section of the kidney



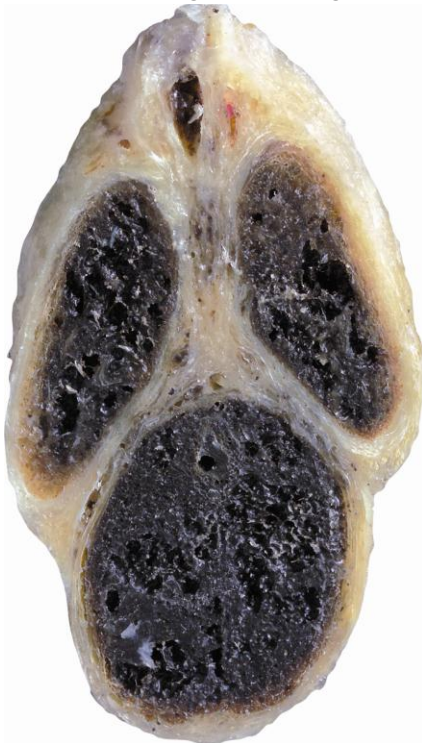Art – N0 / S U 010
The seminal vesicles, ampulla
ductus deferentis and prostate



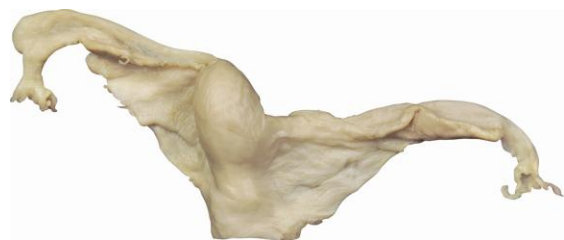Art – N0 / S U 011
The male genital organs



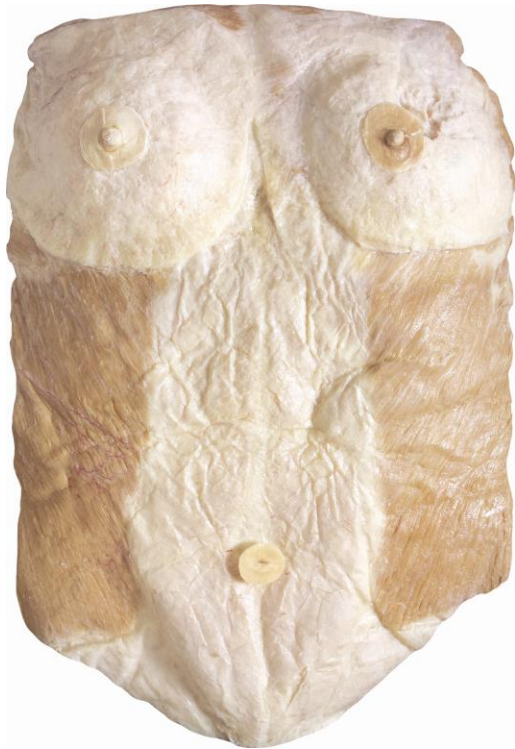Art – N0 / S U 013
Cavernous body of penis



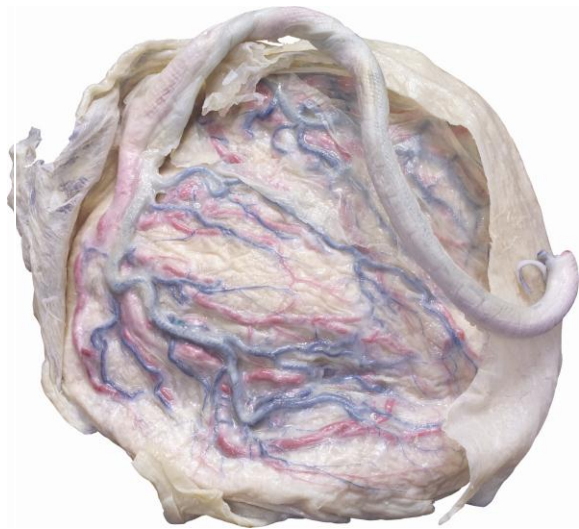
Art – N0 / S U 014
Transverse section of penis



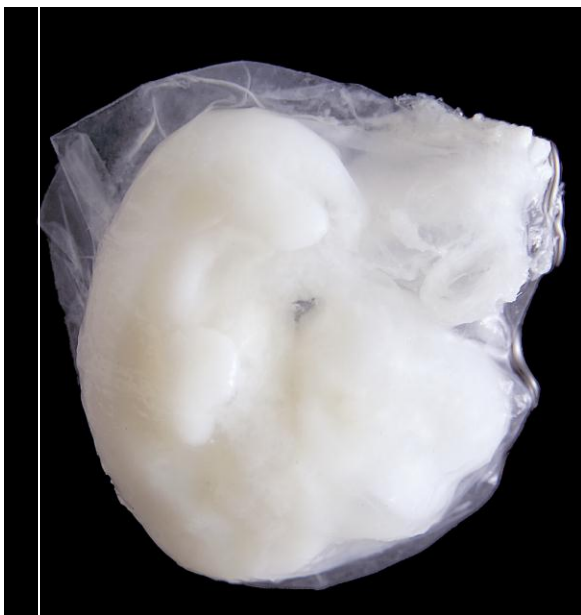Art – N0 / S U 016
The female internal reproductive
organs



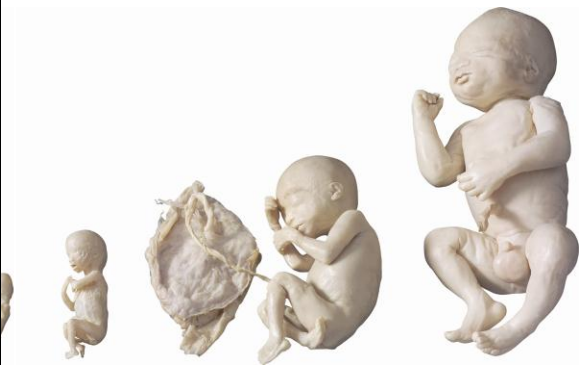Art – N0 / S U 018
The female mamma



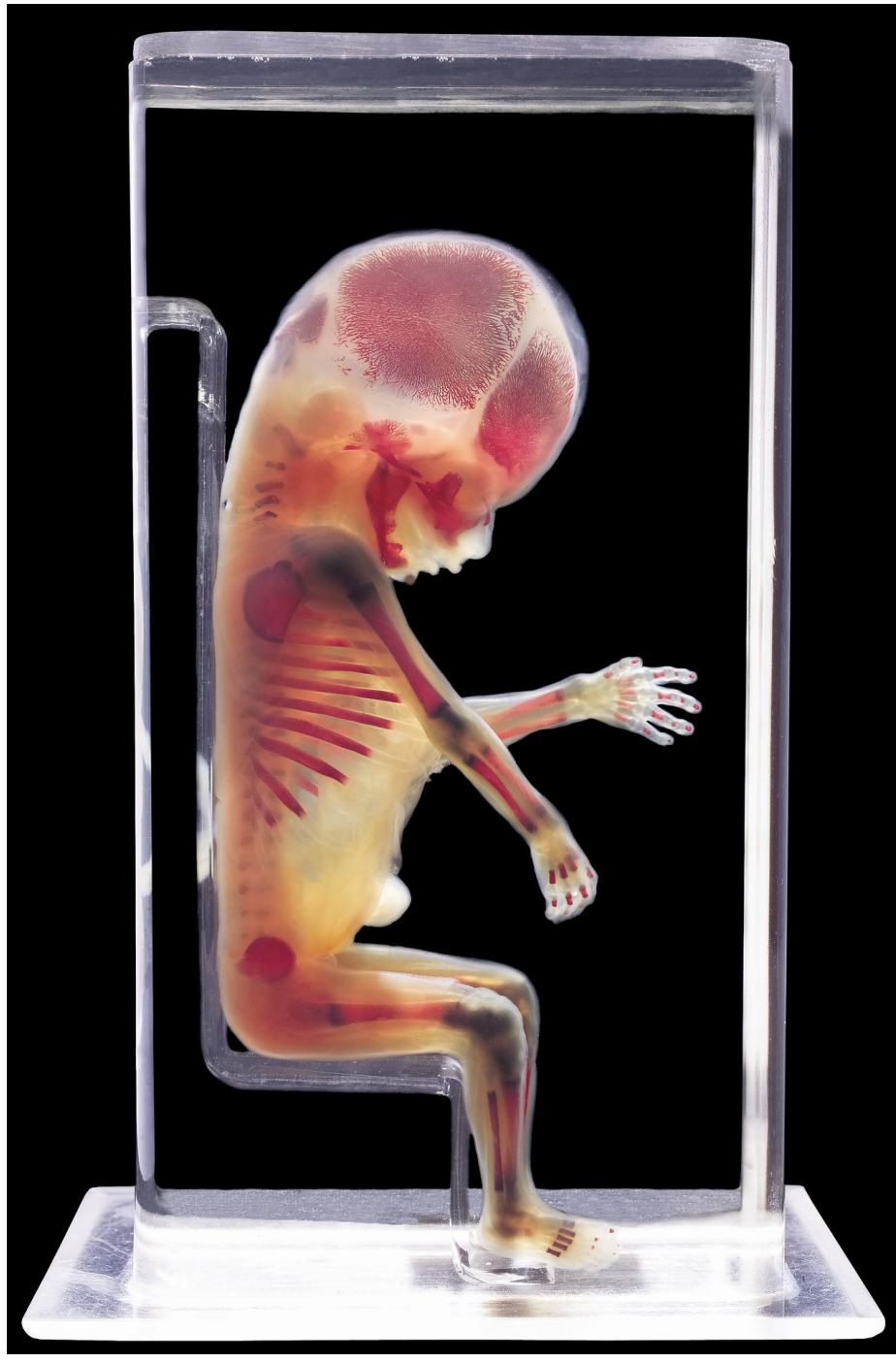Art – N0 / S U 019
The placenta



Art – N0 / S U 020
Embryos



Art – N0 / S U 021tus
featus



Art – N0 / S U 022
The development of fetal cartilage